

## **Bilateral Choroidal Folds in a Diabetic Patient**

Masoud Reza Manaviat<sup>1\*</sup>, Samira Salimpour<sup>2</sup>

1- Department of Ophthalmology, Shahid Sadoughi University of Medical Sciences, Yazd, Iran  
2- Geriatric Ophthalmology Research Center, Shahid Sadoughi University of Medical Sciences, Yazd, Iran

**\*Correspondence:**

Masoud Reza Manaviat, Department of Ophthalmology, Shahid Sadoughi University of Medical Sciences, Yazd, Iran  
**Tel:** (98) 351 8224000  
**Fax:** (98) 351 8224100  
**Email:** mr\_manaviat@yahoo.com

**Received:** 05 June 2014

**Accepted:** 11 August 2014

**Published in September 2014**

### **Abstract**

In this presentation, a case of bilateral choroidal folds in patient with diabetic retinopathy was reported. By our knowledge, this case presentation is the first report of choroidal folds in diabetic retinopathy, which bilateral symmetric and horizontal folds arranged in macula. The thick choroid that is developed in diabetics may be a cause of these folds but the source of difference in patterns is unknown.

### **Keywords:**

Choroidal fold, Chorioretinal fold, Diabetic retinopathy

## **Introduction**

**C**horoidal folds were first described in 1884 in association with papillitis (1). After that, evaluations revealed that they have been associated with some various conditions such as optic disc drusen and hyperopia. Also, it was seen that choroidal folds were accompanied by conditions like central serous retinopathy, choroidal nevi, orbital tumors and papilledema. Moreover, hypotony of the globe observed especially after surgical procedures and post-operative choroidal edema or inflammation can cause choroidal folds. However in some cases the etiology may be unclear which is referred to as idiopathic choroidal folds (2-4).

Choroidal folds may be unilateral or bilateral; however bilateral choroidal folds are uncommon (3). Here, a case of bilateral choroidal folds in association with diabetic retinopathy is presented. This case was unpretentious and had no alteration after two years follow up.

### **Case Report**

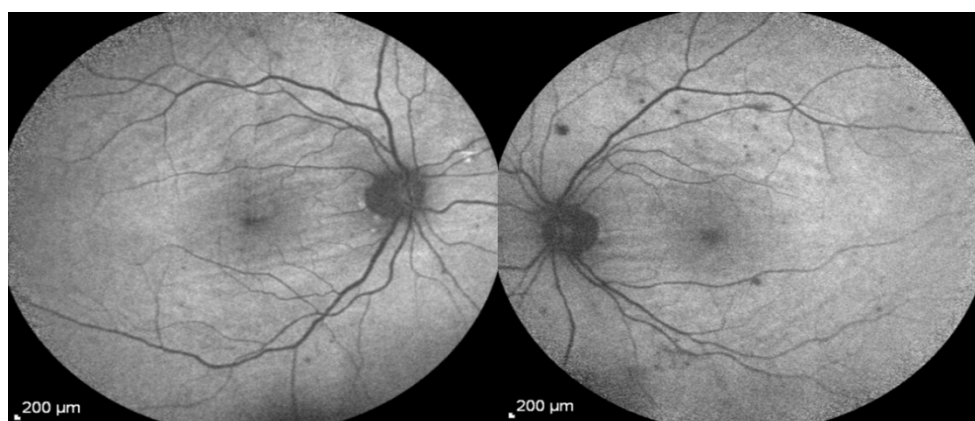A 50 year old man was examined for routine checkup for diabetic retinopathy. He had no complain of eye problems and no history of previous ophthalmic disorder leading to medical treatment and surgical procedure.

Examination revealed visual acuity 20/20 in both eyes with no refractive error. Intraocular pressures of both eyes were within normal range. The anterior segment was unremarkable in both eyes. There was no afferent pupillary defect. Funduscopy disclosed evidence of nonproliferative diabetic retinopathy and multiple fine chorioretinal folds in both eyes: wrinkles of the fundus characterized by an ophthalmoscopic aspect of alternating yellow and dark streaks roughly parallel with one another. The folds were horizontally orientated. There were no papilledema, drusen, retinal detachment, or other pathological changes (Figure 1).

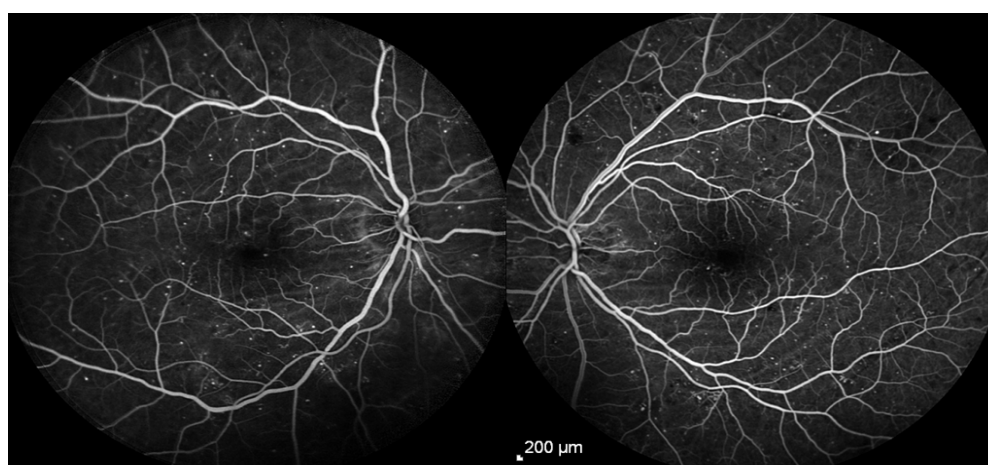
Fluorescein angiography (FA) demonstrated bands with typical alternating hypofluorescence and hyperfluorescence of the choroidal folds. The bands appeared from the early phase throughout late phase.

Fluorescein angiography remarked vascular changes which were compatible with funduscopy examination: mild nonproliferative diabetic retinopathy (Figures 2,3).

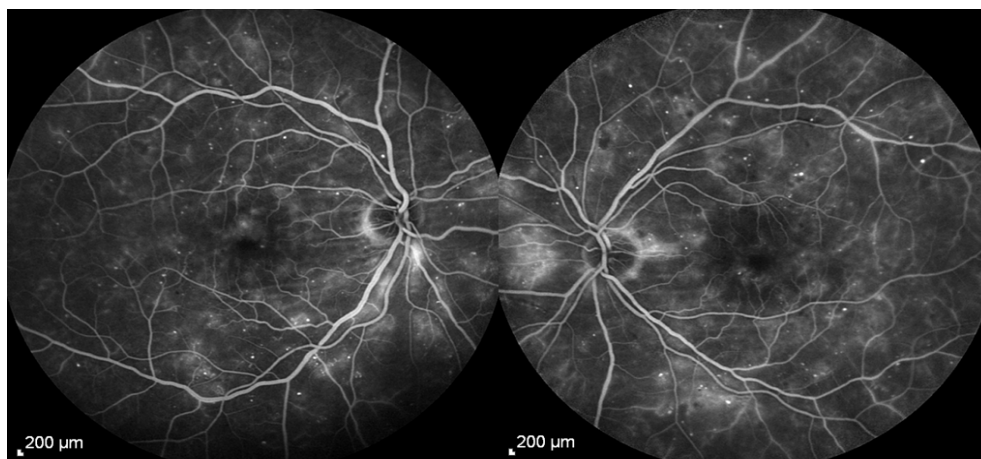
Optical coherence tomography (OCT) revealed the wavy appearance of the retinal pigment epithelium as well as the underlying choroid. The retinal surface appeared flat and the thickness of the retina was variable, adapting itself to the crests and valleys of the folds. Increased penetration of the beam toward the choroid was present in the valleys of the folds in comparison with the crests. This OCT pattern is referred to as choroidal folds, where the undulation is caused by wrinkling of the internal choroid, retinal pigment epithelium (RPE), and Bruch's membrane but the inner retina, the softer layer, is adapted to wrinkling and saves its inner surface flatness.



**Figure 1. Red-free photographs of right and left eyes.**



**Figure 2. Early phase of fluorescein angiography.**



**Figure 3. Late phase of fluorescein angiography**

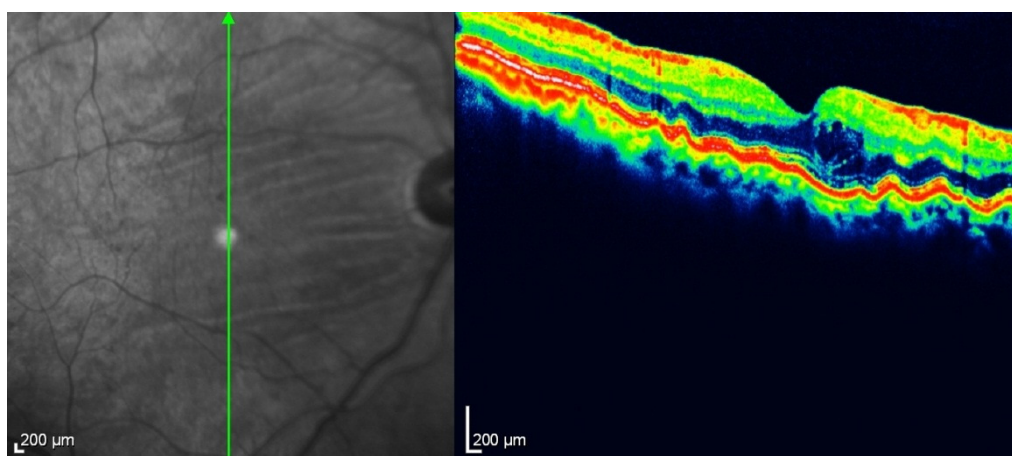
Average retinal thickness of both eyes was normal; only an increase in foveal thickness in right eye was found compared to the left eye (358 vs. 273 µm) (Figures 4,5).

After 2 year follow up, the patient was asymptomatic and funduscopy examination

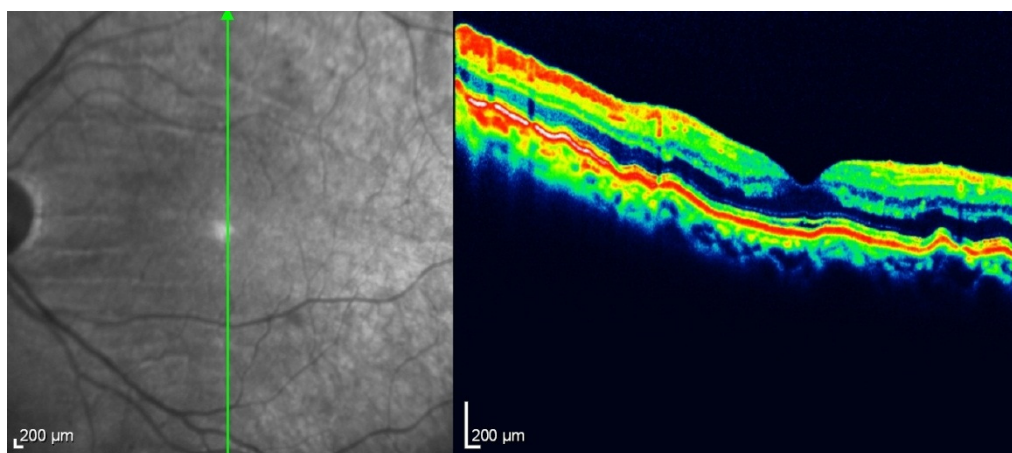
was invariant. Hyperopic shift was not indicated.

### Discussion

In the presented case, funduscopy examination and paraclinic evaluation



**Figure 4. OCT of the right eye.**



**Figure 5. OCT of the left eye.**

revealed bilateral choroidal folds in the patient with nonproliferative diabetic retinopathy.

FA is one of the imaging modalities to document the findings. This modality is helpful in differentiating retinal from chorioretinal and choroidal folds. If the wrinkling involves only the retina, FA does not show changes in the background fluorescence; while sodium fluorescein leaks quickly out of the choroidal vessels and stains the choroid. However, because the RPE effectively filters out most of background fluorescence, the choroid appears gray rather than white. In the setting of the choroidal folds in which the RPE cells are compressed, the RPE becomes a more efficient filter. On the other hand, when the choroid and RPE are stretched, this efficiency will be reduced. Final effect is that choroidal folds appear as alternating dark and light bands on FA.

However, FA cannot differentiate chorioretinal from choroidal folds. OCT shows how the retina, RPE and choroid are all folded and what their relationships and thicknesses are. The cross-section image provided by OCT can detect the wavy appearance of the choroid. The elastic properties of the choroid and sensory retina are different. Hence the retina can, to some degree, internally adjust along the underlying choroidal folds (5).

In this presentation, the case of bilateral choroidal folds was reported. As is known, choroidal folds may be a sign of an ocular disease. Hence, when approaching a patient with choroidal folds, the major consideration is to find the source of the disorder. Choroidal folds are developed due to biomechanical stresses, for instance, from an extraocular mass in the orbit pressing upon the globe, from thickening of the choroid from hypotony, choroidal effusion or inflammation, or from stresses secondary to a growing choroidal tumor. Due to these etiologies, choroidal folds are usually unilateral and the bilateral type which is seen in our patient is uncommon. Bilateral type can be in association with a benign condition such as hyperopia. Progressive shortening of the globe by

flattening of the posterior curvature in hyperopic patients may be resulted in choroidal folds that are usually arranged in horizontally or obliquely pattern. Hyperopic shift in older than 40 years old is a characteristic feature. The two year follow-up of the present research revealed no hyperopic progression; hence hyperopic shift is not considered as an associated problem. Broad, irregular bands that are located vertical or even radial outward from optic disc are seen in hypotony of globe. Also, orbital space-occupying lesions usually produce folds emanating from optic disc. Choroidal neoplasms or neovascularization, by displacement and contracture of surrounding tissue, will produce choroidal folds which radiate outward the lesion. When no pathologic condition is found in association with chorioretinal folds, they are considered to be idiopathic (3,4,6).

In the literature, there is not enough data about relationship between diabetic retinopathy and choroidal folds, but a recent review of diabetics' angiographies revealed choroidal folds in 16 cases. They are usually symmetric in both eyes. The patients were usually asymptomatic and the prognosis in them was typically favorable. Bend-shaped, horizontal, concentric, outside the macula and variable length were the characteristics of choroidal folds reported in these 16 cases of diabetic retinopathy and choroidal folds (7).

In conclusion, this case presentation is the first report of choroidal folds in diabetic retinopathy, in which bilateral symmetric and horizontal folds arranged in macula. The thick choroid that is developed in diabetics may be a cause of these folds, but the source of difference in patterns is unknown.

### Acknowledgment

The authors would like to thank Yazd diabetes research center for their support and Ms Azardokht Zare for her assistance in coordinating the imaging aspects of this study and providing images for evaluation.

## References

1. Nettleship E, Peculiar lines in the choroid in a case of postpapillitic atrophy. *Trans Ophthalmol Soc UK* 4:1678
2. Jaworski, Wolffsohn, Napper. Aetiology and management of choroidal folds. *ClinExpOptom*. 1999; 82: 5: 169–176
3. Shrier EM, McGroarty JF. Bilateral Chorioretinal Folds in Association with Chronic Polypoidal Choroidal Vasculopathy. *J Ocular Biol*. 2013; 1(2): 2
4. Newell FW. Fundus changes in persistent and recurrent choroidal folds. *Br J Ophthalmol* 1984 68: 32-35
5. Giuffre G, Distefano MG. Optical coherence tomography of chorioretinal and choroidal folds. *ActaOphthalmol Scand*. 2007 May;85(3):333-6.
6. Lorraine M Cassidy, Michael D Sanders. Choroidal folds and papilloedema. *Br J Ophthalmol* 1999 83: 1139-1143
7. Fagundez Vargas MA, Jimenez Parras R, Bermudez Uria L. Choroidal folds in diabetic retinopathy. *Arch SocEspOftalmol*. 2000 Dec; 75(12):797-802