

Intravitreal Injection of Bevacizumab (Avastin) to Treat Posterior Capsule Neovascularization

Masoud-Reza Manaviat, Zohreh Chiti*

Yazd Diabetes Research Center, Shahid Sadoughi University of Medical Sciences, Yazd, Iran

Received: 12 December, 2009 - Accepted: 15 January, 2010

ABSTRACT

We report a 64-year-old diabetic woman who developed neovascularization of the posterior capsule 2 years after cataract surgery and intraocular lens implantation. The patient was treated with single injection of 1.25 mg of intravitreal bevacizumab (Avastin) via pars plana. After one week, complete regression of the posterior capsule neovascularization was achieved allowing us to perform Nd: YAG capsulotomy without serious complications. Intravitreal injection of bevacizumab can successfully regress the posterior capsule neovascularization resulting in improving patient's visual acuity.

KEYWORDS: Intravitreal injection, Bevacizumab (Avastin), Posterior capsule neovascularization.

INTRODUCTION

The progression of diabetic retinopathy into proliferative state is expected in diabetic patients. One of the hallmarks of this progression is neovascularization frequently as rubeosis iridis and neovascular glaucoma. However, developing new vessels at the posterior capsule, a condition which was first termed as rubeosis capsulare by Eifrig et al., is a rare condition with no conventional treatment (1).

Vascular endothelial growth factor (VEGF) is well known as a key factor in the development of retinal neovascularization, and its blockade has been observed to regress retinal as well as iris new vessels (2). Bevacizumab (Avastin; Genentech, Inc, South San Francisco, CA, USA) is a humanized monoclonal anti-VEGF antibody and has been used in the treatment of various ocular neovascularization (2).

Here, we present a case of posterior

capsule neovascularization in a diabetic patient who demonstrated a complete regression of the new vessels with single dose of intravitreal bevacizumab injection.

MATERIALS AND METHODS

A diabetic patient with extensive posterior capsular neovascularization, who is presented below, was identified during the clinical practice. The University Ethics Committee approval was then obtained and the experiment was conducted with the understanding and the consent of the patient. It was conducted in accordance with the Declaration of Helsinki (1964).

CASE REPORT

A 64-year-old woman attended in ophthalmology clinic of Yazd Diabetes Research Center with complaint of progressively visual loss of both eyes. She had a 30-year history of type 2 diabetes mellitus

*Correspondence: Zohreh Chiti, Yazd Diabetes Research Center, Jomhuri Blvd., Yazd, Iran.

Tel: (+98) 351 522 3999. Fax: (+98) 351 525 8354. E-mail: z.chiti@gmail.com

which was initially treated with hypoglycemic agents and more recently by insulin therapy. The patient also had a history of phacoemulsification with intraocular lens implantation of her right eye two years ago.

In the physical examination, she had a visual acuity of count fingers at 3 meters in the right eye and 2 meters in the left eye. The intraocular pressure of both eyes was 16 mmHg. In the slit lamp examination, right eye had clear cornea with mild neovascularization of iris and extensive posterior capsular neovascularization with posterior capsular opacification (Figure 1). A clear cornea, normal iris, and a cataractous lens were found in the slit-lamp examination of patient's left eye. Retinal examination revealed changes corresponding to the severe stage of non-proliferative diabetic retinopathy (NPDR) in her both eyes. However, the posterior capsule neovascularization precluded further and careful examination of the right retina. Therefore, to overcome this problem and also to improve the patient's visual acuity, a treatment with intravitreal injection of bevacizumab was suggested to her.

An intravitreal injection of 1.25 mg bevacizumab was administered to the patient's right eye via pars plana. After treatment, the patient was under close observation for any sign of infection or increased intraocular pressure. After one week, a complete regression of the capsular neovascularization as well as iris neovascularization was observed (Figure 2).

An Nd: YAG capsulotomy was then performed without any complications (Figure 3). The visual acuity of the patient's right eye was increased to 20/80. No recurrence of neovascularization was observed after 6 months of follow-up.

DISCUSSION

Although posterior capsule neovascularization is a rare complication of diabetic retinopathy, undoubtedly it interferes with diabetic retinopathy treatments such as retinal photocoagulation and vitrectomy. Although no conventional modalities have been observed to

be able to treat this condition, other modalities such as photodynamic therapy have been reported to successfully regress the neovascularization of the posterior capsule in recent case report (3).

However, intravitreal administration of bevacizumab has been successfully used in the treatment of rubeosis iridis and neovascular glaucoma (4,5) and to our knowledge there are only three reported cases in the literature in which intravitreal injection of bevacizumab is used to treat posterior capsule neovascularization (6,7 and 8).

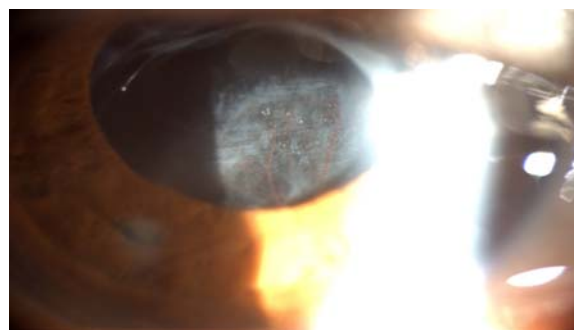


Figure 1- Slit lamp view of patient's right eye before intravitreal injection of Avastin shows extensive posterior capsule neovascularization.

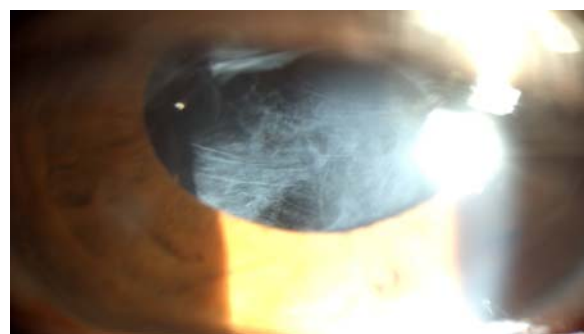

Figure 2- Slit lamp view of patient's right eye one week after intravitreal injection of Avastin shows complete regression of capsule neovascularization.

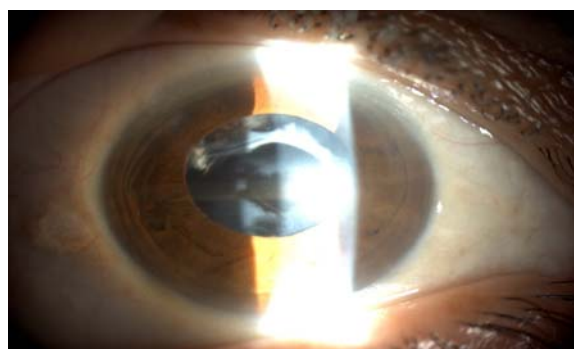


Figure 3- Slit lamp view of the same eye after capsulotomy.

These three cases all had diabetic retinopathy and underwent panretinal photocoagulation. They developed posterior capsule neovascularization following the cataract surgery. In two of the cases the new vessels regressed completely after single injection of intravitreal bevacizumab, but in the remaining case a second dose became necessary to further decrease the neovascularization.

In our case, a single administration of intravitreal bevacizumab was sufficient to

completely regress the new vessels developed at the posterior capsule and subsequently enabled us to perform the Nd: YAG capsulotomy which increased the visual acuity of the patient substantially.

In summary, intravitreal injection of bevacizumab offers an effective and safe alternative treatment to regress the posterior capsule neovascularization with none or minimal complications.

REFERENCES

1. Eifrig DE, Hermsen V, McManus P, Cunningham R. Rubeosis capsulare. *J Cataract Refract Surg* 1990; 16:633–6.
2. Avery RL, Pearlman J, Pieramici DJ, Rabena MD, Castellarin AA, Nasir MA, et al. Intravitreal bevacizumab (Avastin) in the treatment of proliferative diabetic retinopathy. *Ophthalmology* 2006; 113:1695–705.
3. Ayata A, Unal M, Erşanlı D, Gülecek O, Sönmez M. Photodynamic therapy for posterior capsule neovascularization. *J Cataract Refract Surg* 2007; 33(6):1131-2
4. Mason III JO, Albert Jr MA, Mays A, Vail R. Regression of neovascular iris vessels by intravitreal injection of bevacizumab. *Retina* 2006; 26(7): 839–41.
5. Kahook MY, Schuman JS, Noecker RJ. Intravitreal bevacizumab in a patient with neovascular glaucoma. *Ophthalmic Surg Lasers Imaging* 2006; 37(2): 144–6.
6. Eren E, Kucukerdonmez C, Yilmaz G, Akova YA. Regression of neovascular posterior capsule vessels by intravitreal bevacizumab. *J Cataract Refract Surg* 2007; 33: 1113–5.
7. Sbnchez-Castro GY, Hitos-Fbjer A, Mendoza-Schuster E, Velez-Montoya R, Velasco-Barona CF. Posterior capsule opacification and neovascularization treated with intravitreal bevacizumab and Nd: YAG capsulotomy 2008; 2(3): 657–60.
8. Rajagopal J, Kamath AG, Kamath GG, Rao MM. Intraocular injection of bevacizumab for rubeosis capsulare in a pseudophakic eye. *Eye* 2009; 1.