Orginal Article Open Access
Iranian Journal of Diabetes and Obesity (IJDO)

Protective Effects of the Combination of the Herbal Compound Against Inflammation Related to Obesity and Colitis Induced by Diet in Mice

Fatemeh Azizian-Farsani[1], Navid Abedpoor[2], Maryam Derakhshan[3], Mohammad Hossein Nasr-Esfahani[2], Mohammad Hasan Sheikhha[1,4*], Kamran Ghaedi[5]

[1]Department of Medical Genetics, Shahid Sadoughi University of Medical Sciences, Yazd, Iran.
[2]Department of Cellular Biotechnology, Cell Science Research Center, Royan Institute for Biotechnology, ACECR, Isfahan, Iran.
[3]Department of Pathology, Isfahan University of Medical Sciences, Isfahan, Iran.
[4]Biotechnology Research center, International Campus, Shahid Sadoughi University of Medical Sciences, Yazd, Iran.
[5]Department of Cell and Molecular Biology and Microbiology, Faculty of Biological Science and Technology, University of Isfahan, Isfahan, Iran.

Abstract

Objective: High-fat diet (HFD) rises the susceptibility of both obesity and consequently Inflammatory Bowel Disease (IBD). We designed a study to investigate the improving effects of herbal extract (HE, the combination of turmeric, ginger, boswellia, and cat's claw extract) on the risk of high AGEs-fat diet 60% (HFD) mice induced colitis and obesity.

Materials and Methods: Four-week-old C57BL/6 male mice after 2 weeks adaptation with normal diet were fed with either HFD or normal diets. After 6 weeks of being on diet, animals received HE for 16 weeks. Obesity index markers were determined as well as histological studies using H&E (Hematoxylin-eosin) staining. Colonic expression of *IL-1β* was determined. Data analysis was performed by utilizing Kruskal-Wallis and Mann-Whitney test for post-hoc comparisons, and SPSS (version 17.0) and GraphPad Prism Software (Version 8.0, USA).

Results: HE decreased histological scores (by 6-fold) in HFD diet-fed mice, and reduced myeloperoxidase activity (by 2.2-fold), and ratio of colon weight to length (by 4-fold) in HFD diet-fed mice. Moreover, HE prevented intestinal permeability through the restoration of ZO-1 (by 4-fold) and immune homeostasis by modulation of *IL-1β* (by 2.4-fold) expression.

Conclusion: HFD induced obesity-associated colitis. HE decreased the colitis symptoms in HFD diet-fed mice, with the reduction of inflammation.

Keywords: Colitis, High-fat diet, Herbal extract, Inflammation

QR Code:

Citation: Azizian-Farsani F, Abedpoor N, Derakhshan M, Nasr-Esfahani M H, Sheikhha M H, Ghaedi K. Protective Effects of the Combination of the Herbal Compound Against Inflammation Related to Obesity and Colitis Induced by Diet in Mice. IJDO. 2022; 14 (1) :37-43

URL: http://ijdo.ssu.ac.ir/article-1-685-en.html

10.18502/ijdo.v14i1.8740

Article info:

Received: 08 October 2021

Accepted: 28 December 2021

Published in February 2022

This is an open access article under the (CC BY 4.0)

Corresponding Author:

Mohammad Hasan Sheikhha, [1]Department of Medical Genetics, Shahid Sadoughi University of Medical Sciences, Yazd, Iran.

Tel: (98) 913 357 7387

Email: sheikhha@yahoo.com

Orcid ID: 0000-0002-3734-8970

[Downloaded from ijdo.ssu.ac.ir on 2026-11-24]

[DOI: 10.18502/ijdo.v14i1.8740]

Introduction

Obesity as a global problem has increased recently with the prevalence of 39.8% as stated by the latest national health and nutrition examination survey (1). Obesity increases the risk of Inflammatory Bowel Disease (IBD) as well as Crohn's disease (CD) and ulcerative colitis (UC). IBD is a chronic, recurring, immunoinflammatory illness of unknown cause. High fat diet and life routine promote intestinal damage (2). The Western diet unhealthy combination in favor of high fat and toxic ingredients like advanced glycation end products (AGEs), triggers microbiota change and provoke IBD by stimulating of innate immune system (3-7). Also, environmental issues for instance individual sanitation, smoking cause disease beginning (8). In recent decades, different plants have been vigorously used to overcome UC and IBD, due to their pharmacological properties, fewer reactions and less costly. Epidemiologically, intake of ginger, turmeric, *Boswellia serrata*, and cat's claw was protective against IBD (9-13). Anti-inflammatory properties of their secondary metabolites have been proved in different studies (14-19).

Therefore, in this study, the preventive effects of this herbal combination on high AGEs HFD-induced colitis in male C57/bl6 mice was investigated.

Materials and Methods

Preparation of herbal extract (HE)

Four HEs compound in powder form was purchased from Goldaru Pharmaceutical Company (Esfahan, Iran). HE is composed of four herbs: Turmeric (31%), (Cat's claw) *Uncaria tomentosa* (10%), Ginger (29.5%), and *Boswellia* (29.5%), which was suspended in distilled water and gavaged daily for 16 weeks to the mice groups.

Experimental Design and Animal Diet

Four-week C57BL/6 male mice (12±3 g), attained from the Royan Institute for Biotechnology (Esfahan, Iran), were adjusted under normal situations (temperature 23–24 °C, humidity 32–33%, light/dark cycle of 12 h/12 h) and fed with pellet diets and water *ad libitum*. Water and pellet consumption was measured daily.

Firstly, mice were divided into the two groups of normal diet (ND) (n=6), or high-fat Diet (HFD) (n=12). The two diets ingredients are shown in Table 1. Then, HFD group was separated into 2 groups: one group was continued on an HFD, and the other was given an HFD added with HE 0.6 mg/g (HFD/HE) for 16 weeks (Figure 1A).

After 24-week experimental period, all groups were sacrificed. Colon lengths and weights were measured and blood samples collected and transferred to tubes and centrifuged (3,000 × g for 10 min at 4 °C) for the biochemical analyze. The adipose and colon tissue were divided, weighed, frozen in liquid nitrogen and stored at -80 °C. 1 cm of the distal part of colon tissues was separated for histological investigation.

Myeloperoxidase (MPO) Assay

Colon MPO activity was assessed as a marker of neutrophilic infiltration by using MPO assay kit (NampoxTM, Navand Salamat Co., Iran), according to the protocol (20).

Histologic Examination

Colon tissue samples were fixed in formalin (10%) for one day and surrounded in paraffin, cut into 5μm sections, and stained with H&E (Hematoxylin-eosin**)** and continued with routine protocol and then colonic inflammation was assessed under the microscope and showed as histological score (21).

Biochemical analysis of blood

Plasma total cholesterol, high-density and low-density lipoproteins and triglycerides were assessed using commercial diagnostic kits (Pars Azmoon kit, Pars Azmoon Inc.,

[Downloaded from ijdo.ssu.ac.ir on 2026-11-24]

[DOI: 10.18502/ijdo.v14i1.8740]

Iran), and the plasma glucose was determined by glucometer.

qRT-PCR Analysis

Total RNA isolation was performed by TRIzol reagent (Ambion, USA) and went through DNase treatment (Takara, Japan). Then RNA reverse transcription was done using M-MLV Reverse Transcriptase (Takara, Japan) (15 minutes in 37 ˚C, then 5 seconds in 85 ˚C and hold in 4 ˚C), and the cDNA amplification was done by qPCR by means of SYBR Premix Ex Taq II (Takara, Japan) (Table 2). Primer sequences are presented in supplementary (Table 3). Primers were designed by Beacon designer 7 and Oligo 7. *GAPDH* was used as housekeeping gene.

Statistical analysis

GraphPad Prism Software (Version 8.0Graph Pad Software Inc., USA) was used for analysis. Distribution was assessed by Kolmogorov-Smirnov test. Results are showed as mean and 95% confidence interval (CI). Data were triplicate data sets for each sample and analyzed by One-way analysis of variance (ANOVA). Differences at $P<0.05$ were considered to be significant in all analyses.

Ethical considerations

The protocol of the study and animal practice was accepted by the Ethics Committee of the Royan Institute (IR.SSU.MEDICINE.REC.1396.164).

Results

Effect of oral HE on body weight gain, white adipose tissue (WAT) weight, and lipid profile

A significant difference in the body weight between HFD-fed mice and ND-fed mice ($P< 0.001$) was indicated. After 24 weeks the mice in HFD group start losing weight up to the end of the study. Our data indicated consuming a mix of four HE (Ginger-Turmeric-Frankincense-Cat's claw) significantly reduced the body weights in HFD-fed mice by 1.4-fold (Figure 1B). Moreover, results have showed that HFD-fed mice had higher WAT weight than ND-fed mice. HE caused a significant decrease ($P< 0.001$) in WAT weight by 3-fold (Figure 1C). Also, plasma concentrations of glucose, TG and CHO, HDL and LDL improved significantly in HFD-fed mice in relation to ND-fed mice ($P< 0.05$). HE was effective in declining ($P< 0.05$) of them (Table 4). Moreover, H&E staining of adipose tissue showed that HE significantly diminished the size of adipocytes, decreased the size of visceral (VSC) adipocytes by 3-fold

Effect of HE on symptoms of colitis

IL-1β (by 6-fold) mRNA expression, and MPO activity (by 4-fold) was significantly increased after 30 weeks in HFD-fed mice compared with other groups, showing that colitis was well induced after 30 weeks (Figure 2B and 2C). The HFD-fed mice without HE showed symptomatic weight loss after 24 weeks of receiving HFD. However, the HE HFD-fed group showed a normal increase of weight up to the end of the study rather than mice without HE (Figure 1B). Results indicated that HFD-fed mice possessed higher colon weight to length than ND-fed mice. Interestingly, HE caused a significant reduction ($P< 0.001$) in this parameter (by 4-fold). ($P< 0.001$; Figure 2A).

Also, evaluation of MPO activity as a key neutrophil infiltration marker in the colon demonstrated that it was significantly increased in HFD group than the ND group. HE reduced the level of colonic infiltrated cells induced by the HFD (Figure 2B). Quantitative PCR analysis in colon revealed a chronic inflammation in the HFD group. However, *IL-1β* expression was significantly increased of HFD groups in comparison to the ND group (by 6-fold, $P< 0.001$). In the HFD group, HE regularized *IL-1β* transcripts (by 3-fold). ($P< 0.001$; Figure 2C). Moreover, HE decreased histological score by 6-fold in HFD group (Figure 2D).

[Downloaded from ijdo.ssu.ac.ir on 2026-11-24]

[DOI: 10.18502/ijdo.v14i1.8740]

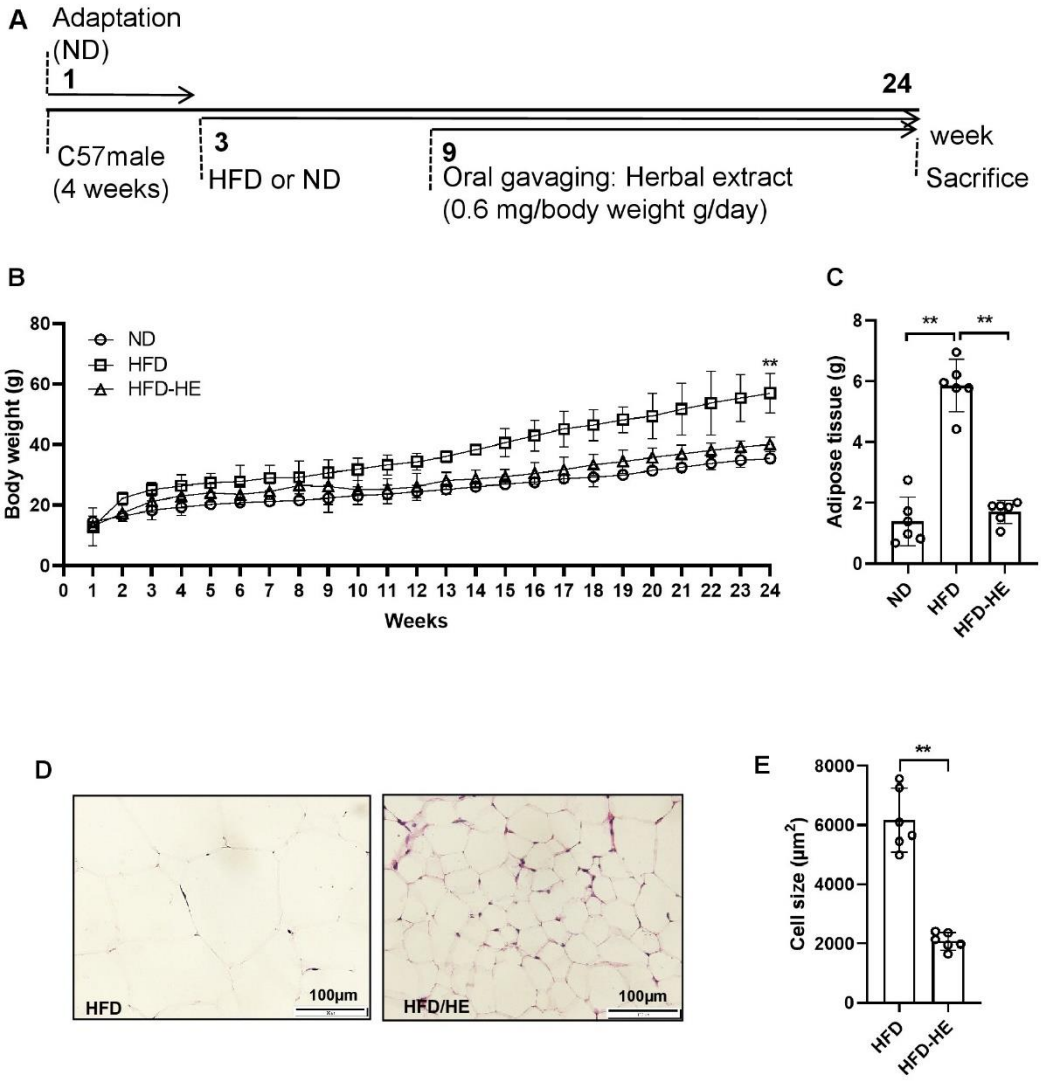

Figure 1. Study design, body, and adipose tissue weight. (A) There are two groups of diet (HFD and ND) that received HFD or ND for 24 weeks. HE treatment began from the 9th week until week 24th. (B) Bodyweight, and (C) trajectories of the adipose tissue weight of each treatment group are shown. (D) Representative images of H&E staining of the visceral adipose tissue section and (E) white adipose tissue (WAT) adipocyte size measurement. HE: herbal extract; ND: normal diet; HFD: high AGEs-fat diet. Data as mean with 95% CI, n=6 per group. ** represents *P*< 0.01.

Table 1. Nutrient content of diets (HFD and ND)

Variable	HFD	Normal
Protein (g %)	25.6	26
Carbohydrate (g %)	26.6	50.3
Fat (g %)	35	5. 35
Calories (kcal/g)	5.2	3.4
Total AGEs (units/mg)	995.4	117.4
Fat-associated AGEs (units/mg)	329.6	1.4
Maltodextrin (g %)	125	25

AGEs: Advanced Glycation End Products, HFD: High AGEs-Fat diet, and ND: Normal diet

[Downloaded from ijdo.ssu.ac.ir on 2026-11-24]

[DOI: 10.18502/ijdo.v14i1.8740]

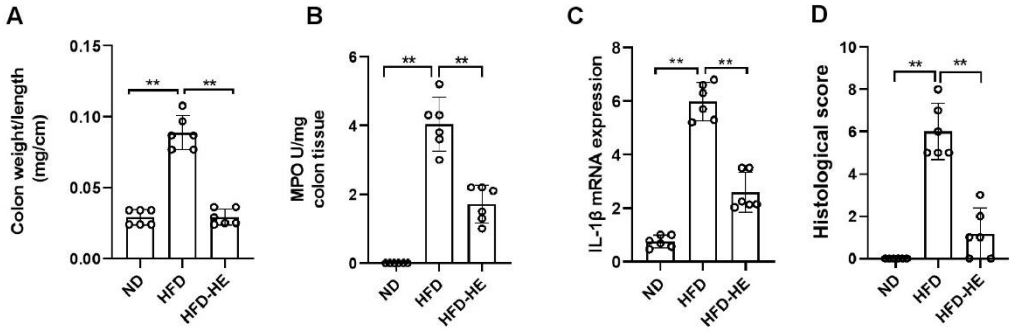

Figure 2. HFD-induced colitis, inflammatory mediators, and histological score. (A) Colon weight to length, (B) MPO activity, (C) mRNA expression of *IL-1β*, (D) Histological score. HE: herbal extract; ND: normal diet; HFD: high AGEs-fat diet. HS: histological score; MPO: myeloperoxidase. Data as mean with 95% CI, n= 6 per group. ** represents *P*< 0.01.

Table 2. Real-time PCR protocol

PCR Amplification		
Hot start	95 ˚C	10 min
Denaturation	95 ˚C	5 sec
Annealing	*PPAR-γ* (60 ℃) *PGC-1α* (60 ℃) *ZO-1* (60 ℃) *IL-1β* (58 ℃) *TGF-β* (59 ℃)	20 sec
Extension	72 ˚C	15 sec
Final extension	72 ˚C	5 min

Table 3. Primer sequences used in this study

Gene	Sequence (5`-3`)
GAPDH	forward: TGCCGCCTGGAGAAACC reverse: TGAAGTCGCAGGAGACAACC
IL-1β	forward: GGGCCTCAAAGGAAAGAATC reverse: TACCAGTTGGGGAACTCTGC

Table 4. HEs effect on Blood parameters.

Blood biochemical indexes (mg/dl)	Groups HFD Mean (±SD)	ND Mean (±SD)	HFD-HE Mean (±SD)	% difference between HFD and HFD-HE
T-CHO	300.23 (±3.1)*	41.12 (±1.1)	171.13 (±5.2)	43%
TGs	345.87 (±4.6)*	23.01 (±1.3)	190.23 (±2.2)	45%
HDLs	5.66± (0.8)*	2.02 (±0.4)	3.26 (±0.6)	42%
LDLs	10.6± (0.39)*	4.12 (±0.5)	5.75 (±0.4)	45%
FBS	310 ± (5.2)*	98 (±1.2)	120 (±2.2)	61%

FBS, Fast blood glucose; HFD, High AGEs-fat diet; HD, High dose; HDLs, high-density lipoproteins; HE, Herbal extract; LDLs, low-density lipoproteins; ND, Normal diet; T-CHO, Plasma total cholesterol; TGs, Triglycerides. Star represents a significant difference with ND parameters at *P*< 0.05, (±SD).

Discussion

HFD increases the risk of obesity, diabetes, hypertension, cardiovascular disease, and also IBD (26). Consumption of HFD increases the contact to food AGEs, and in the long-term promotes inflammation in the colon (3,4,6,7,23-25). Moreover, epidemiologic studies have revealed that there is a correlation between the increase prevalence of obesity and IBD (26). Our study shows that HFD is correlated with obesity and colon inflammation as shown by increasing adipose cell size and elevating IL-1β in the colon. Of note, HE strikingly prevented obesity and general inflammation.

The mutual characteristics of colitis are immune cell recruitment and activation by cytokines and cell adhesion molecules (27,28). Neutrophils produce pro-inflammatory cytokines such as IL-6, IL-1β, IL-17, and IFN-γ, and enhance the expression of oxidative

[Downloaded from ijdo.ssu.ac.ir on 2026-11-24]

[DOI: 10.18502/ijdo.v14i1.8740]

stress enzyme, iNOS, promoting colitis. Moreover, a westernized diet strengthens colitis as indicated by elevating MPO activity (7). Herbal medicines such as turmeric, *Boswellia*, ginger, and cat's claw have already testified to reduce inflammatory cell infiltration into the colon. In parallel, we showed that HFD improved immune cell recruitment and MPO elevated activity in the colon, which were alleviated by HE. We found that the combination of these four HEs faster the recovery of colitis symptoms. In support of our findings, turmeric, ginger, *Boswellia serrata* and cat's claw are valuable sources of curcuminoids, alkaloids, and polyphenolics, and volatile oils (terpenes), protective against IBD and colorectal cancer (9-13).

Conclusions

Altogether, our results evidenced that combination of ginger, turmeric, boswellia, and cat's claw can lessen colitis severity related to HFD induced obesity and colitis, with the reduction of inflammation.

Acknowledgments

The authors express their sincere gratitude to the colleagues and staffs at Royan Institute of Isfahan.

Funding

This research supported under Iran National Science Foundation projects funding scheme (project number 97004431) and Shahid Sadoughi Medical University of Yazd.

Conflict of Interest

The authors have no conflicts of interest.

References

1. Hales CM, Carroll MD, Fryar CD, Ogden CL. Prevalence of obesity among adults and youth: United States, 2015–2016.
2. Ding S, Chi MM, Scull BP, Rigby R, Schwerbrock NM, Magness S, et al. High-fat diet: bacteria interactions promote intestinal inflammation which precedes and correlates with obesity and insulin resistance in mouse.Journal of PlOS ONE. 2010;5(8):e12191.
3. Kato S, Itoh K, Ochiai M, Iwai A, Park Y, Hata S, et al. Increased pentosidine, an advanced glycation end-product, in urine and tissue reflects disease activity in inflammatory bowel diseases. Journal of gastroenterology and hepatology. 2008;23:S140-5.
4. Kim IW, Myung SJ, Do MY, Ryu YM, Kim MJ, Do EJ, et al. Western-style diets induce macrophage infiltration and contribute to colitis-associated carcinogenesis. Journal of gastroenterology and hepatology. 2010;25(11):1785-94.
5. Kellow NJ, Coughlan MT. Effect of diet-derived advanced glycation end products on inflammation. Nutrition Reviews. 2015;73(11):737-59.
6. Snelson M, Coughlan MT. Dietary advanced glycation end products: digestion, metabolism and modulation of gut microbial ecology. Nutrients. 2019;11(2):215.
7. van der Logt EM, Blokzijl T, van der Meer R, Faber KN, Dijkstra G. Westernized high-fat diet accelerates weight loss in dextran sulfate sodium-induced colitis in mice, which is further aggravated by supplementation of heme. The Journal of nutritional biochemistry. 2013;24(6):1159-65.
8. Karlinger K, Györke T, Makö E, Mester Á, Tarján Z. The epidemiology and the pathogenesis of inflammatory bowel disease. European journal of radiology. 2000;35(3):154-67.
9. Anthoni C, Laukoetter MG, Rijcken E, Vowinkel T, Mennigen R, Muller S,et al. Mechanisms underlying the anti-inflammatory actions of boswellic acid derivatives in experimental colitis. American Journal of Physiology-Gastrointestinal and Liver Physiology. 2006;290(6):G1131-7.
10. Murakami A, Furukawa I, Miyamoto S, Tanaka T, Ohigashi H. Curcumin combined with turmerones, essential oil components of turmeric, abolishes inflammation-associated mouse colon carcinogenesis. Biofactors. 2013;39(2):221-32.
11. Peterson CT, Vaughn AR, Sharma V, Chopra D, Mills PJ, Peterson SN, Sivamani RK. Effects of turmeric and curcumin dietary supplementation on human gut microbiota: A double-blind, randomized, placebo-controlled pilot study.Journal of Evidence-Based Integrative Medicine.2018;23. https://doi.org/10.1177/2515690X18790725.
12. Yuan X, Sun H, Liu Y, Shiroshita T, Kawano S, Takeshi S, et al. Anti-cancer activity comparisons of aqueous extracts from Inonotus obliquus,

[Downloaded from ijdo.ssu.ac.ir on 2026-11-24]

[DOI: 10.18502/ijdo.v14i1.8740]

Cordyceps militaris and Uncaria tomentosa in vitro and in vivo. Journal of Pharmacognosy and Phytochemistry. 2014;2(6).
13. Zhang L, Xue H, Zhao G, Qiao C, Sun X, Pang C, et al. Curcumin and resveratrol suppress dextran sulfate sodium-induced colitis in mice. Molecular medicine reports. 2019;19(4):3053-60.
14. Alizadeh M, Kheirouri S. Curcumin against advanced glycation end products (AGEs) and AGEs-induced detrimental agents. Critical reviews in food science and nutrition. 2019;59(7):1169-77.
15. Chilelli NC, Ragazzi E, Valentini R, Cosma C, Ferraresso S, Lapolla A, et al. Curcumin and boswellia serrata modulate the glyco-oxidative status and lipo-oxidation in master athletes. Nutrients. 2016;8(11):745.
16. Dil FA, Ranjkesh Z, Goodarzi MT. A systematic review of antiglycation medicinal plants. Diabetes & Metabolic Syndrome: Clinical Research & Reviews. 2019;13(2):1225-9.
17. Starowicz M, Zieliński H. Inhibition of advanced glycation end-product formation by high antioxidant-leveled spices commonly used in European cuisine. Antioxidants. 2019;8(4):100.
18. Vaughn AR, Branum A, Sivamani RK. Effects of turmeric (Curcuma longa) on skin health: a systematic review of the clinical evidence. Phytotherapy Research. 2016;30(8):1243-64.
19. Zhu Y, Zhao Y, Wang P, Ahmedna M, Sang S. Bioactive ginger constituents alleviate protein glycation by trapping methylglyoxal. Chemical research in toxicology. 2015;28(9):1842-9.
20. Mahmoudi T, Abdolmohammadi K, Bashiri H, Mohammadi M, Rezaie MJ, Fathi F, et al. Hydrogen peroxide preconditioning promotes protective effects of umbilical cord vein mesenchymal stem cells in experimental pulmonary fibrosis. Advanced pharmaceutical bulletin. 2020;10(1):72.
21. Kim KA, Gu W, Lee IA, Joh EH, Kim DH. High fat diet-induced gut microbiota exacerbates inflammation and obesity in mice via the TLR4 signaling pathway.Journal of Plos one. 2012. https://doi.org/10.1371/journal.pone.0047713.
22. Loftus Jr EV. Clinical epidemiology of inflammatory bowel disease: incidence, prevalence, and environmental influences. Gastroenterology. 2004;126(6):1504-17.
23. Chuyen NV, Arai H, Nakanishi T, Utsunomiya N. Are food advanced glycation end products toxic in biological systems?. Annals of the New York Academy of Sciences. 2005;1043(1):467-73.
24. DeClercq V, McMurray DN, Chapkin RS. Obesity promotes colonic stem cell expansion during cancer initiation. Cancer letters. 2015;369(2):336-43.
25. Vlassara H. Advanced glycosylation in nephropathy of diabetes and aging. Advances in nephrology from the Necker Hospital. 1996;25:303-15.
26. Harper JW, Zisman TL. Interaction of obesity and inflammatory bowel disease. World journal of gastroenterology. 2016;22(35):7868.
27. Randhawa PK, Singh K, Singh N, Jaggi AS. A review on chemical-induced inflammatory bowel disease models in rodents. The Korean journal of physiology & pharmacology. 2014;18(4):279-88.
28. Luster AD. Chemokines—chemotactic cytokines that mediate inflammation. New England Journal of Medicine. 1998;338(7):436-45.

[Downloaded from ijdo.ssu.ac.ir on 2026-11-24]

[DOI: 10.18502/ijdo.v14i1.8740]