

A Case of Adrenocorticotropin -Independent Macronodular Adrenal Hyperplasia (AIMAH)- A Case Report

Seyed Mohammad Mohammadi¹, Golnaz Malekzadeh^{2*}

1. Endocrinologist, Internal Medicine Department of Shahid Sadoughi University of Medical Sciences, Yazd, Iran.
2. Internal Medicine Resident, Internal Medicine Department of Shahid Sadoughi University of Medical Sciences, Yazd, Iran.

***Correspondence:**

Golnaz Malekzadeh, Internal Medicine Resident, Internal Medicine Department of Shahid Sadoughi University of Medical Sciences, Yazd, Iran.

Tel: (98) 913 253 6332

Email: Golnaz_malek_zade@yahoo.com

Received: 04 May 2019

Accepted: 02 August 2019

Published in August 2019

Abstract

The case-report is about a 47 year old woman with adrenocorticotropin-independent macronodular adrenal hyperplasia (AIMAH), with is a rare cause of endogenous Cushing's syndrome. Urin free cortisol (UFC) and cortisol of 8AM were elevated along with the suppressed level of ACTH. Abdominal CT scan showed macronodules in both adrenals .The patient underwent left adrenalectomy and pathological data confirmed the diagnosis. The patient has been inhormon replacement therapy after surgery.

Keywords: Macronodular adrenal hyperplasia, Cushing's syndrome, Cortisol

Introduction

Adrenocorticotropin-independent macronodularadrenal hyperplasia (AIMAH) is a rare cause of endogenous Cushing's syndrome associated with Mccun- Albright's syndrome in particular (1). Numerous bilateral enlarged macronodules (more than 1 cm) in adrenal glands that produce too much cortisol independently of ACTH that leads to the development of Cushing's syndrome. This disease is more prevalent in middle-aged women (2).

The diagnosis is based on the clinical presentation confirmed by the hormonal tests and imaging. The ultimate diagnosis is made through the pathological findings of the adrenal tissue (3). Adrenalectomy is the choice treatment .Unilateral adrenalectomy can be done to preserve the moderate secretion of cortisol; however, the bilateral adrenalectomy is needed in significant overproduction of cortisol (4).

Case presentation

A 47 year old woman was admitted in Shaid Sadoughi Hospital endocrinology department because of hypothyroidism and hypertension. She was previously diagnosed with a secondary hypothyroidism and was under treatment with levothyroxine. The thyroid function tests as well as the physical examination of the thyroid were normal, however, she complained about the proximal muscle weakness and mild limb edema with no other signs or symptoms of Cushing's syndrome.

The level of the other endocrine hormones was checked to find out the cause of the weakness, the hormonal investigation revealed the elevated prolactin and the UFC with normal plasma cortisol at 8AM along with suppressed ACTH. (Table 1)

Due to the elevated prolactin, the patient underwent a pituitary magnetic resonance imaging (MRI) which was normal. The UFC and plasma cortisol level at 8AM were done again. The UFC had elevated while the cortisol at 8AM was normal. The plasma level of cortisol was not suppressed after the dexamethason suppression test (99.96, RR: 60-285 ng/ml). The sequential lab data was done, the patient underwent an abdominal computed tomography scan (CT scan) showing bilateral adrenal macronodules and an AIMAH case was diagnosed with regards to the available data. (Figure 1)

Due to the lack of access to cholesterol-based radionuclides scan, and because of the left side larger nodules, she underwent left adrenalectomy.

Hormonal investigation revealed hypocortisolism with normal UFC in a month, therefore, the replacement therapy was done hydrocortisone as well as fludrocortison.

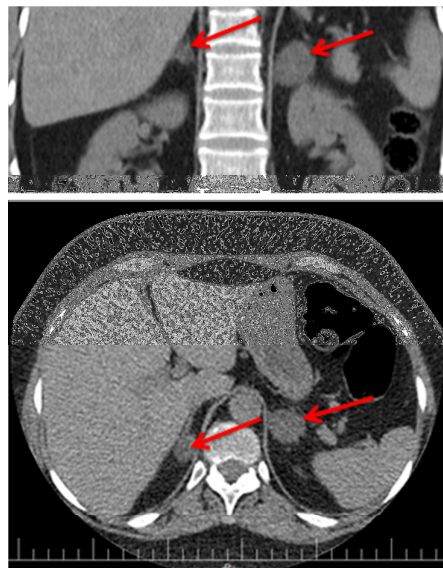


Figure 1. The bilateral adrenal nodules in Abdominal CT Scan

Discussion

This report indicates a rare case of Cushing's syndrome which was ACTH independent that macronodules in adrenal produced too much cortisol. The development of the hypercortisolism was sort of slow. Our patient was a subclinical Cushing's syndrome with subtle symptoms and signs.

The diagnosis was merely through the patient's muscle weakness and lab data.

This disease is mainly prevalent among the middle-aged females like our patient.

The lab data in these patients usually show low ACTH with a high level of cortisol and no dexamethason suppression exactly like our case (5,6). The imaging findings confirm the causes, even though, the nodules cannot sometimes be distinguished from the normal adrenal which necessitates the pathological report for its confirmation (7).

Table 1. The laboratory findings

Hormonal test	Level	Refrence range
TSH	0.1	0.27-6.22 (uIU/ml)
T4	90.15	60-120 (nmol/lit)
Cortisol at 8AM	64.07	60-285 (ng/ml)
ACTH	<0.1	7.2-63.3 (pg/ml)
UFC	370	50-190 (Micg/24h)
Prolactin	40.63	5-35 (ng/ml)

The treatment of AIMAH depends on the severity of hypercortisolism. Unilateral adrenalectomy can be considered for the patients with moderate increase in level of cortisol while bilateral adrenalectomy is needed in severe cases.

Bilateral adrenalectomy brings about the necessity of the hormone replacement therapy (8). The unilateral adrenalectomy was done, however, the hormones were suppressed and she was in need of hydrocortisone and fludrocortisone tablets.

References

1. Hamajima T, Maruwaka K, Homma K, Matsuo K, Fujieda K, Hasegawa T. Unilateral adrenalectomy can be an alternative therapy for infantile onset Cushing's syndrome caused by ACTH-independent macronodular adrenal hyperplasia with McCune-Albright syndrome. *Endocrine journal*. 2010;1005260424.
2. Lacroix A. ACTH-independent macronodular adrenal hyperplasia. *Best practice & research Clinical endocrinology & metabolism*. 2009;23(2):245-59.
3. Costa MH, Lacroix A. Cushing's syndrome secondary to ACTH-independent macronodular adrenal hyperplasia. *Arquivos Brasileiros de Endocrinologia & Metabologia*. 2007;51(8):1226-37.
4. Iacobone M, Albiger N, Scaroni C, Mantero F, Fassina A, Viel G, et al. The role of unilateral adrenalectomy in ACTH-independent macronodular adrenal hyperplasia (AIMAH). *World journal of surgery*. 2008;32(5):882-9.
5. Su HC, Dai J, Huang X, Zhou WL, Huang BX, Cao WL, et al. Classification, diagnosis and treatment of ACTH-independent macronodular adrenal hyperplasia. *Canadian Urological Association Journal*. 2013;7(9-10):E594.
6. Li QL, Guo RM, Chen LH, Yin QL, Wang YN, Chen YM. The clinical characteristics of 10 cases of adrenocorticotrophic hormone-independent macronodular adrenal hyperplasia. *Zhonghua nei ke za zhi*. 2013;52(9):737-40.
7. Li J, Yang CH. Diagnosis and treatment of adrenocorticotrophic hormone-independent macronodularadrenocortical hyperplasia: A report of 23 cases in a single center. *ExpTher Med*. 2015;9(2):507-512.
8. Zhang TB, Li R, Zhang WX, Sun YY, Wang R, Wang CL, et al. Laparoscopic Subcutaneous Transposition of a Pedicled Adrenal for ACTH-Independent Bilateral Macronodular Adrenal Hyperplasia. *Journal of Laparoendoscopic & Advanced Surgical Techniques*. 2016;26(8):641-5.

Conclusions

The patient's complaints may sometimes cause the diagnosis of some rare diseases. The recognition of which can never been accessible without precise scrutiny. This case revealed a rare type of Cushing's syndrome with muscle weakness without any other significant symptoms or signs.

Acknowledgments

We would like to appreciate Mr M.M Mirhosseini.